

Current Applications of Facial Volumization with Fillers

Anthony J. Wilson, M.D.
 Anthony J. Taglienti, M.D.
 Catherine S. Chang, M.D.
 David W. Low, M.D.
 Ivona Percec, M.D., Ph.D.

Philadelphia, Pa.



Learning Objectives: After reading this article and watching the accompanying videos, the participant should be able to: 1. Assess patients seeking facial volumization and correlate volume deficiencies anatomically. 2. Identify appropriate fillers based on rheologic properties and anatomical needs. 3. Recognize poor candidates for facial volumization. 4. Recognize and treat filler-related side effects and complications.

Summary: Facial volumization is widely applied for minimally invasive facial rejuvenation both as a solitary means and in conjunction with surgical correction. Appropriate facial volumization is dependent on patient characteristics, consistent longitudinal anatomical changes, and qualities of fillers available. In this article, anatomical changes seen with aging are illustrated, appropriate techniques for facial volumization are described in the setting of correct filler selection, and potential complications are addressed. (*Plast. Reconstr. Surg.* 137: 872e, 2016.)

Over the past three decades, anatomical advances by means of cadaver dissection and medical imaging have highlighted volume loss as a principal cause of facial aging. Initial volumization techniques emphasized dermal and superficial subcutaneous injections; however, recently, there has been a paradigm shift in treating the aging face with deep tissue correction. Because of the rapid expansion of minimally invasive cosmetic facial interventions, it is critical that aesthetic surgeons maintain proficiency in these approaches to optimize patient outcomes in a longitudinal and comprehensive manner. It is equally important to educate noncore medical specialists engaging in nonsurgical cosmetic rejuvenation about the limitations and dangers of these approaches and when such treatments may not be constructive for a given patient. This article instructs the reader about tissue dynamics of the aging face, current temporary soft-tissue fillers and injection techniques, detailed injection methods for the correction of specific facial zones of volume loss, and potential injection complications.

TEMPORARY FILLERS AND THEIR CHARACTERISTICS

The two principal categories of temporary fillers approved by the U.S. Food and Drug

Administration for facial rejuvenation are hyaluronic acid and calcium hydroxylapatite. The semipermanent filler polymethylmethacrylate, the biostimulator poly-L-lactic acid, and autologous fat represent distinct alternatives with unique biological properties and injection techniques, and thus are discussed here.¹⁻¹⁷ Hyaluronic acid fillers were introduced for intradermal injection in the United States in 2003 and have since become the predominant fillers for soft-tissue augmentation.¹⁸⁻²⁶ Current U.S. Food and Drug Administration–approved hyaluronic acid fillers are produced by means of nonanimal stabilized hyaluronic acid technology; however,

Disclosure: Dr. Percec is a paid consultant for Galderma. All interaction with Galderma occurred after the submission of this CME article. Consultation has regarded products not included in this article. All products were used from stock supply of the Division of Plastic Surgery at the University of Pennsylvania with the exception of six syringes of Restylane Silk supplied by Galderma prior to its commercial release in the United States. Drs. Wilson, Taglienti, Chang, and Low have no financial disclosures to report.

Related Video content is available for this article. The videos can be found under the “Related Videos” section of the full-text article, or, for Ovid users, using the URL citations published in the article.

From the University of Pennsylvania, School of Medicine.
 Received for publication March 12, 2015; accepted February 3, 2016.

Copyright © 2016 by the American Society of Plastic Surgeons

DOI: 10.1097/PRS.0000000000002238

Table 1. Commonly Used Hyaluronic Acid and Calcium Hydroxylapatite Fillers Currently Approved by the U.S. Food and Drug Administration*

Name	Elasticity (G')	Viscosity (n*)	HA Concentration (mg/ml)	Relative Injection Depth	Lidocaine	FDA Approval Date
Restylane†	514	119,180	20	Superficial-medium	No	2003
Restylane-L†	565	131,310	20	Superficial-medium	Yes	2010
Restylane Silk†	459	107	20	Superficial-medium	Yes	2014
Restylane Lyft†	549	127,090	20	Medium-deep	Yes	2010
Belotero Balance‡	30	9217	22.5	Superficial	No	2011
Radiesse‡	1407	349,830	NA	Medium-deep	No	2006
Radiesse(+)‡	~1180	~310,000	NA	Medium-deep	Yes	2015
Juvederm Ultra XC§	111	27,034	24	Superficial-medium	Yes	2006
Juvederm Ultra Plus XC§	136	32,152	24	Medium-deep	Yes	2010
Juvederm Voluma XC§	274	92,902	20	Medium-deep	Yes	2013
Prevelle Silk	230–260	NA	5.5	Superficial	Yes	2008

HA, hyaluronic acid; FDA, U.S. Food and Drug Administration; NA, not available.

All G' and n measured at 0.7 Hz, physiologically relevant for skin stress [Sundaram H, Voigts B, Beer K, Meland M. Comparison of the rheological properties of viscosity and elasticity in two categories of soft tissue fillers: Calcium hydroxylapatite and hyaluronic acid. *Dermatol Surg.* 2010;36(Suppl 3):1859–1865; and Kablik J, Monheit GD, Yu L, Chang G, Gershkovich J. Comparative physical properties of hyaluronic acid dermal fillers. *Dermatol Surg.* 2009;35(Suppl 1):302–312]. Relative injection depth is divided into superficial (deep dermis to superficial subcutaneous), medium (subcutaneous), and deep (deep subcutaneous to bone) levels, and should be tailored to the patient's soft-tissue quality and anatomy. Duration of product depends on injection depth, anatomical site injected, and product blending, and can range from a few months to several years. As discussed in the text, most filler applications are conducted off label.

†Galderma.

‡Merz Aesthetics, Lausanne, Switzerland.

§Allergan, Inc., Irvine, Calif.

||Mentor Corp., Santa Barbara, Calif.

novel fillers produced by means of alternate technologies such as the Emervel (Galderma, Lausanne, Switzerland) line, manufactured by means of optimal balance technology, will likely enter the market. Calcium hydroxylapatite (Radiesse; Galderma) is another temporary filler with properties similar to those of hyaluronic acids. In this article, we focus on hyaluronic acid- and calcium hydroxylapatite-based soft-tissue facial augmentation.

Temporary soft-tissue fillers are classified by their composition and rheologic properties, specifically, elasticity (G'), viscosity (n*), hydrophilicity, particle size, particle concentration, and crosslinking (Table 1).^{8,27} G' describes a material's ability to resist compression, whereas n* refers to a material's ability to resist shearing forces.⁸ Hydrophilicity is the product's capacity to attract water and expand. Particle size, as determined by the polymerization of the glycosaminoglycan chains and straining techniques, contributes to the filler's overall "lifting and filling power."^{8,28,29} Increased particle concentration and crosslinking strengthens hyaluronic acid durability by means of resistance to enzymatic degradation. These properties differ between fillers, with each product being characterized by a unique set of rheologic features. Consequently, these variables must be judiciously taken into consideration

relative to a patient's specific anatomy and soft-tissue characteristics during facial volumization (Figs. 1 and 2).

TEMPORARY FILLER INJECTION TECHNIQUES

Multiple injection techniques exist for soft-tissue volumization (Fig. 3). The proper technique is dependent on injector preference and training, product selected, and anatomical region addressed.³⁰ For superficial and dermal filling, injectors most often use a threading approach, or less often, fanning or cross-hatching techniques in a retrograde or anterograde manner. Deep volumization techniques in the subcutaneous and periosteal planes more frequently include tower-ing, layering, and depot injections. Irrespective of injection technique and tissue depth, aspiration before product injection is recommended to avoid intravascular injection. Product blending with sterile saline, lidocaine, or lidocaine with epinephrine may be chosen in specific anatomical zones and product combinations to tailor rheologic properties.

Injectors have recently begun using blunt cannulae in place of sharp needles.^{31,32} This technique may lead to increased patient comfort, a reduction in edema and ecchymoses, and a more

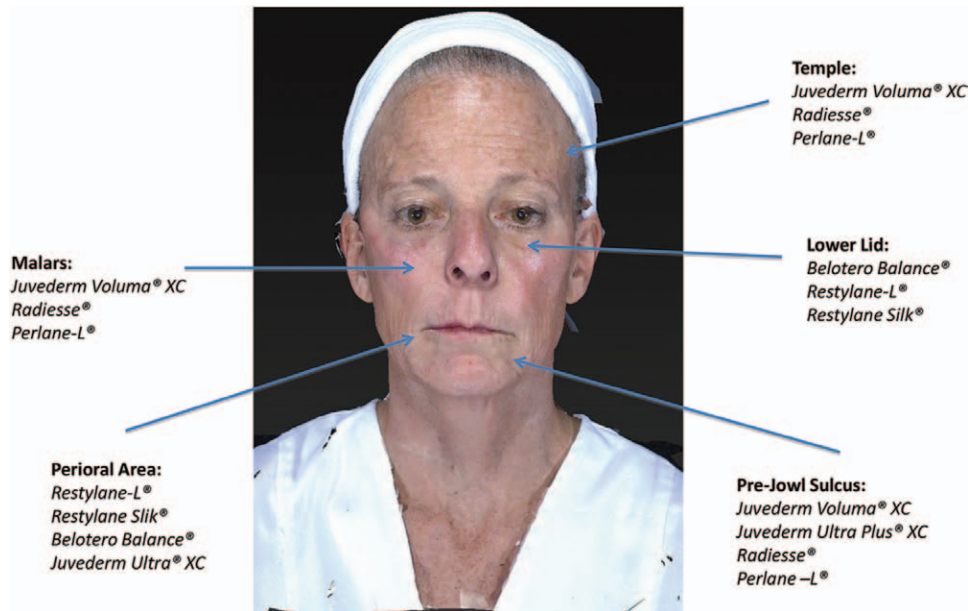


Fig. 1. Image demonstrating suggested filler choices per region. Notably, fillers listed here may not have a U.S. Food and Drug Administration–approved indication for the particular region and are therefore used in an off-label fashion. Fillers with high G' and n^* are best for deep augmentation of the face, whereas fillers with low G' and n^* are best for subcutaneous and dermal volumization.

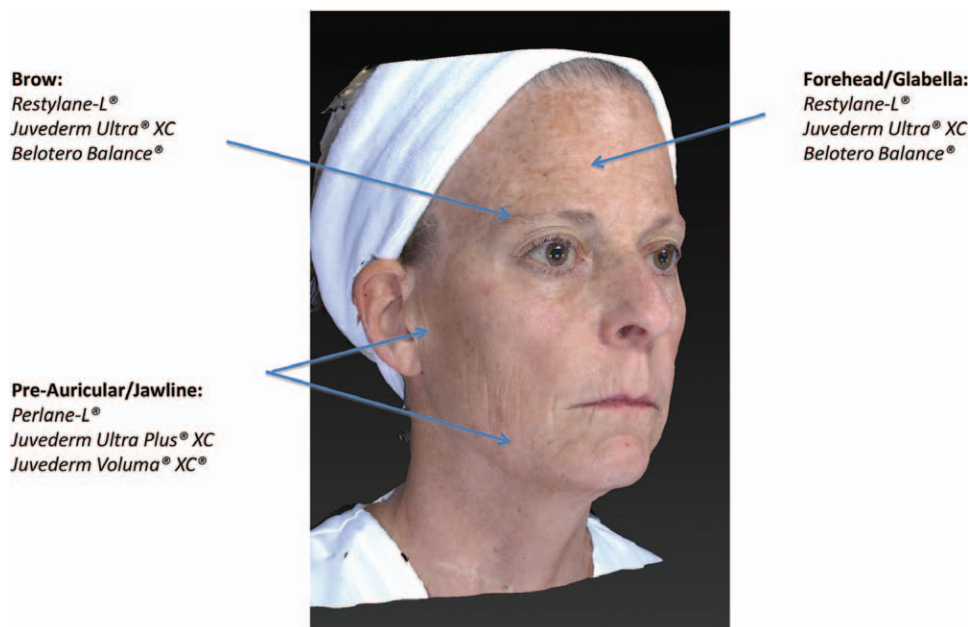


Fig. 2. Image demonstrating suggested filler choices per region. Notably, fillers listed here may not have U.S. Food and Drug Administration–approved indication for the particular region and are therefore used in an off-label fashion. Fillers with high G' and n^* are best for deep augmentation of the face, whereas fillers with low G' and n^* are best for subcutaneous and dermal volumization.

predictable recovery. (See Video, Supplemental Digital Content 1, which displays how the nasojugal groove is treated with a blunt cannula technique, available in the “Related Videos” section of

the full-text article on www.PRSJournal.com or at <http://links.lww.com/PRS/B692>.) Cannulae may be preferable to needles in regions prone to bruising or at higher risk for potential intravascular

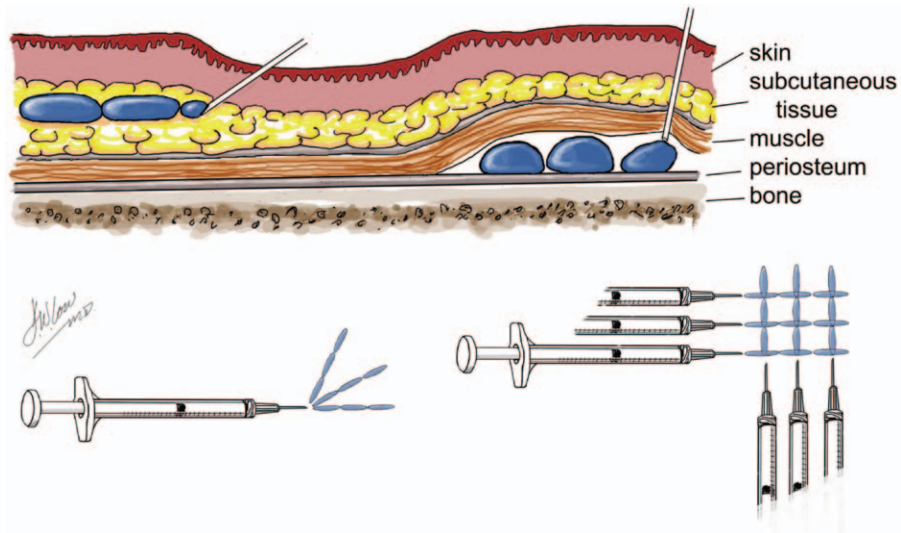
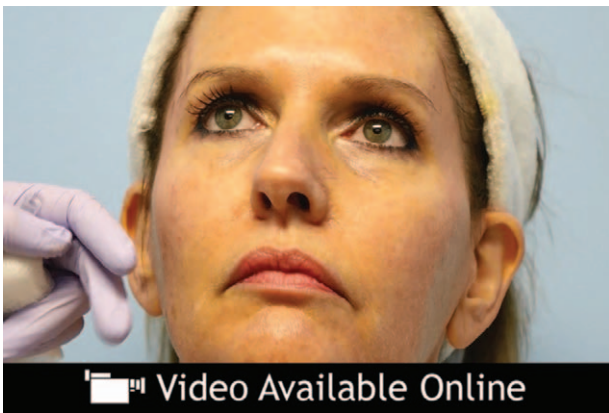


Fig. 3. Injection techniques. (Above, left) Linear threading. Here the needle is inserted and gently retracted while placing consistent pressure, creating a linear deposit of filler. This method, as shown here, is appropriate for subcutaneous and dermal filling of folds and fine lines. (Above, right) Depot injections. For deeper injections the needle is advanced to the level of the bone and retracted slightly. Bolus amounts of filler are then deposited. This technique is often used for malar augmentation with high-G' fillers. (Below, left) Fanning technique. From a single insertion point, the needle is pivoted in multiple angles, placing the product in linear threads along multiple planes. (Below, right) Cross-hatching technique. Used for larger areas for an even distribution of filler. This is appropriate for dermal and subcutaneous filling.



Video 1. Supplemental Digital Content 1, which displays how the nasojugal groove is treated with a blunt cannula technique, is available in the “Related Videos” section of the full-text article on www.PRSJournal.com or at <http://links.lww.com/PRS/B692>.

injection, or when the patient cannot tolerate a standard recovery period. Despite these benefits, many injectors still prefer needle injection techniques, citing additional training for using cannulae, increased cost, difficulty threading the cannulae, and impaired ability to treat all areas effectively. It remains to be determined whether cannula-based techniques will expand and

potentially replace needle-based approaches in the United States.

CHARACTERIZING AND TREATING FACIAL VOLUME LOSS

For consistent and effective facial analysis, it is helpful to consider the topography of the face as being divided into thirds (i.e., the upper face, midface, and lower face). Each region undergoes characteristic volume atrophy or hypertrophy that is combined with increased overall facial strain and an overall decrease in soft-tissue integrity (Fig. 4).^{33–46} Specific changes vary between individuals depending on the patient’s underlying bony structure, weight, and soft-tissue quality.¹⁶ In this article, the anatomical changes associated with aging are described for each third of the face, from the top down and deep to superficial, to simulate clinical scenarios for facial assessment and structural volumization design. For each region, volume correction will address bony and soft-tissue atrophy. Rhytide-specific and superficial (deep-dermal) augmentation is highlighted last as a finishing effect, after structural volumization. Patient assessment

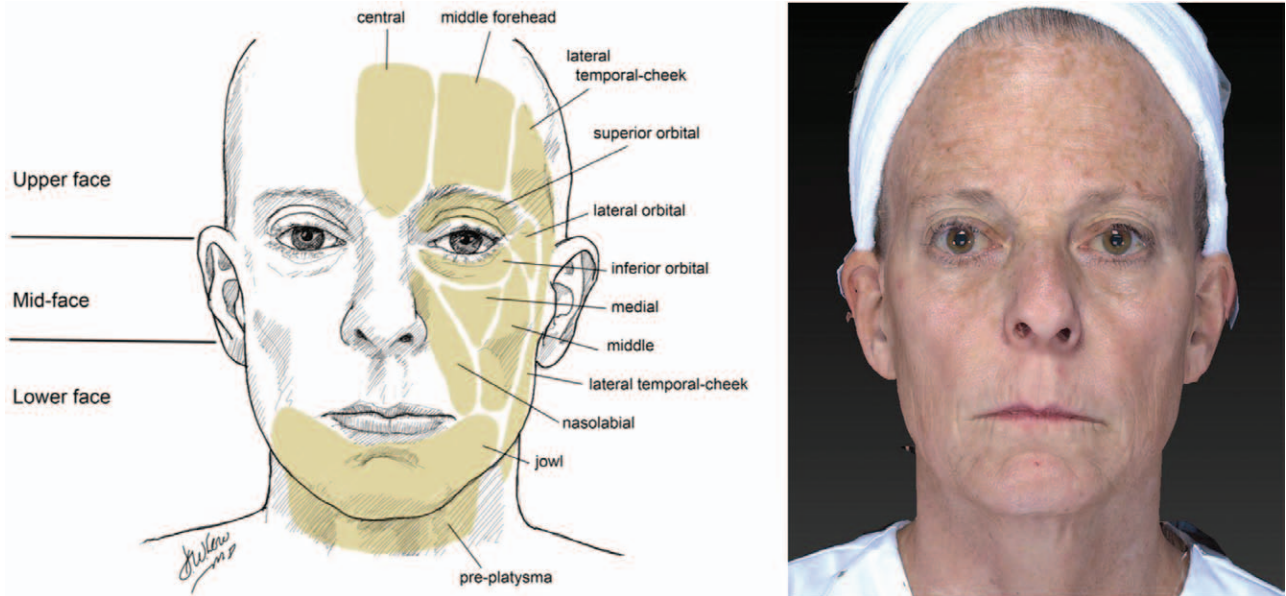


Fig. 4. During facial analysis, the topography of the face is often divided into the upper face, midface, and lower face. For volumization assessment, the upper face is composed of the temples, brows, and periorbital areas, and occasionally the forehead. The mid-face is composed of the malar, submalar, and preauricular regions; the nasolabial folds; and the nose. The lower face is composed of the posterior, middle, and anterior jawline; the perioral area; and the lips. Each region contains anatomically compartmentalized fat pads (labeled), which undergo characteristic and often predictable volume changes.

for each facial region is described, as is the rationale for filler selection and injection techniques. Examples of total facial volumization are provided (Figs. 5 and 6).

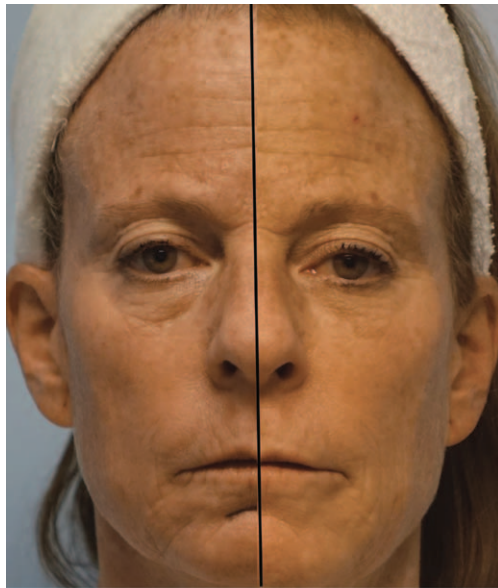METHODOLOGY

Patients that were appropriate medical candidates for filler injections were selected for characteristic age-related facial volume loss. Patients were instructed to avoid aspirin and nonsteroidal antiinflammatory drugs for 1 week before injection. Patients' faces were washed of makeup, and three-dimensional images were taken with the Canfield Vectra System (Canfield Scientific, Fairfield, N.J.) and by means of standard digital photography. LMX 4% topical anesthetic cream (Ferndale Laboratories, Inc., Ferndale, Mich.) was applied to areas to be injected for 15 minutes. The LMX cream was removed and the patients' faces were cleansed first with isopropyl alcohol (70%) and then with chlorhexidine gluconate 4% solution immediately before injection. Injections were conducted as described in the figure legends and videos. After the procedure, injection sites were treated with cold packs for 10 minutes followed by photography. Repeated images of patients were obtained 2 weeks after injection.

Upper Face: Temples, Brows, and Superior Periorbital Area

The youthful upper face is characterized by a subtle convexity of the temple, forehead, and lateral brow and fullness of the upper eyelids.¹⁶ During aging, there is incremental volume loss in these regions. Although the severity of volume loss varies between patients, the ensuing temporal narrowing and periorbital hollowing remain underrecognized and undertreated.^{39,47} Temporal narrowing may result in decreased lateral brow support, with consequent lateral brow ptosis and pseudodermatochalasis of the upper lid. These changes give an overall tired, aged appearance to the upper face, and often represent the first signs of facial aging in the fourth decade of life (Fig. 7).

Upper facial volume loss is secondary to both bony and deep soft-tissue changes. Specifically, there is remodeling of periorbital bone in the superomedial and inferolateral directions, resulting in an altered and vertically lengthened orbital aperture, and an increased susceptibility to lower lid hollowing and contour deformities.^{37,41,42,48,49} Soft-tissue atrophy of the upper face occurs in defined sites of adipose deposition. At the temple, the deep temporal fat pad and the temporal extension of the buccal fat pad atrophy. The forehead and lateral brow undergo thinning of the subcutaneous plane, and the upper lids typically



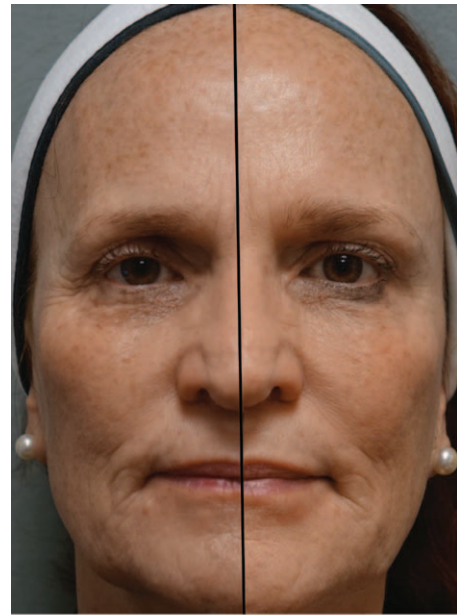PRE

POST

Fig. 5. This 57-year-old patient has panfacial volume loss in the setting of low body mass index and extrinsic aging secondary to prolonged solar exposure. Both images are of her right side, with the postinjection photograph a mirror image 2 weeks after injection. In the upper face, there is mild volume loss at the temple and upper orbital rim. There is significant volume loss of the lower periorbital region with prominent lower lid bags and tear trough deformity. In the midface, there is significant atrophy of the medial and middle malar fat pads. In the lower face, the upper lip has lengthened and there is significant atrophy of cutaneous and mucosal/vermillion lip with a prominent submental sulcus. She received 2 cc of Juvederm Voluma XC to the bilateral malars, 1 cc of Juvederm Voluma XC to the preauricular region bilaterally, and 1 cc to bilateral jaw lines and prejowl sulcus; 1.5 cc of Radiesse was placed into each temple. Each lower lid and nasojugal groove was filled with 0.5 cc of Belotero Balance. The perioral region was augmented with 1 cc of Restylane-L in the oral commissure and lip columns and an additional 1 cc of Restylane Silk to the upper and lower lip vermilions and vermillion border. Three-dimensional progressive augmentation images are demonstrated in Figure 11.

lose volume in the retro-orbicularis oculi fat pad and the medial and lateral fat pads.

The correction of upper facial volume loss at the temple and the upper brow requires fillers with appropriate rheologic properties for deep volumization, specifically an elevated G' and n^* , whereas fillers for volumization of the upper lid, forehead, and crow's feet should possess lower G' and n^* profiles (Figs. 1 and 2).^{50,51} Currently, there are no U.S. Food and Drug Administration–approved fillers for treatment of these regions and thus fillers are used in off-label fashion for these



PRE

POST

Fig. 6. A 58-year-old woman with upper facial volume loss resulting in an aged appearance. Both preinjection and postinjection images are of her right side, with the postinjection image being a mirror image. The patient has not undergone any surgical or minimally invasive treatment. In the upper face, there is atrophy at both the temple and the brow. Before injection, the temple demonstrates significant hollowing, with prominent zygomatic arches, orbital rims, and temporal crests. In addition, there are prominent veins and stigmata of solar elastosis of the skin overlying the temple. In the lower face, there is loss of vermillion volume and emphasized jowls secondary to volume loss in the prejowl sulcus. Given its rheologic properties, Juvederm Voluma XC is used for upper facial augmentation in this patient, although Radiesse and Restylane Lyft are also acceptable options. One cubic centimeter of product was required in each temple for appropriate effacement of temporal hollow, blending of temporal crest, and softening of the prominent orbital rim and zygomatic arch. A total of three injections were performed in each temple: 0.5 cc of Restylane-L was injected into the lateral brow, and a total of 0.5 cc of Belotero Balance was injected into the medial and lateral orbital rims. Thirty units of abobotulinumtoxinA was injected into the lateral orbicularis oculi, and 10 units of onabotulinumtoxinA was injected into the frontalis. The result is a natural softening of the superior and inferior orbital rim and effacement of the pronounced temporal crest and zygomatic arch. In the mid and lower face, she had 1.5 cc of Juvederm Voluma XC to bilateral malars, 0.5 cc of Juvederm Voluma XC to the nasal sill, and 0.5 cc of Restylane Lyft to the prejowl sulcus bilaterally; 1 cc of Restylane-L was injected into the lips and commissures.

indications. Restylane Lyft, Radiesse, and Juvederm VolumaXC and Juvederm Ultra Plus XC are suitable for the deep treatment of the temple and upper brow.⁵⁰ The increased G' of these products



Fig. 7. (Above) A 57-year-old woman without any prior facial surgery or volumization. (Left) Photograph illustrating the youthful face (age 21 years). With age (above, center and above, right), there is volume loss in the highlighted regions, specifically, the temporal fat pad, the malar fat pads, the nasal sill, and the prejowl sulcus. All of these regions are amenable to volumization. (Below) Patient at age 21 (below, left) and at age 59 years (below, right). Notably, in the upper face, there is volume loss at the temples and superior orbital rim. In the midface, there is mild volume loss of the inferior orbit and slight malar deflation. In the lower face, there is perioral volume loss with effacement of the vermilion border and vermilion and volume loss at the prejowl sulcus with resultant jowls.

allows for precise placement on the periosteum, providing structural and lifting support to overlying tissues with a low likelihood of displacement. Restylane-L, Restylane-Silk, Belotero Balance, and Juvederm Ultra XC are suitable fillers for superficial treatment of the temple, upper brow, and eyelid. Selection is based on injector experience, desired product duration, and cost.

We have come to appreciate that the anatomical order of contouring influences the ultimate outcome of facial volumization. Augmentation of the temple alone may provide lateral brow support and therefore should be addressed before moving more caudally. When injecting the temple, careful attention must be paid to the location of temporal

vessels and superficial veins (Fig. 8). Our preferred injection plane is supraperiosteal. Using a 27-gauge needle and the perpendicular depot technique, the needle is advanced to the periosteum. Aspiration is performed and the product is deposited. Serial injections are associated with an increased risk of ecchymosis and injury to critical structures, but may provide more discriminative results. (See Video, Supplemental Digital Content 2, which displays potential techniques for upper facial volumization, with a focus on the temple and the brow, available in the “Related Videos” section of the full-text article on www.PRSJournal.com or at <http://links.lww.com/PRS/B693>.) This approach, in our opinion, provides the longest lasting and

added to the subcutaneous fat of the brow and/or retro-orbicularis oculi fat pad (see **Video, Supplemental Digital Content 2**, <http://links.lww.com/PRS/B693>). Notably, some authors advocate direct suborbicularis injection in the upper lid. Although direct injection in this plane may provide an effective way of correcting upper lid hollowing, given the proximity to the globe and its vasculature, this approach poses additional risks and should be limited to expert injectors.

Midface: Inferior Periorbital Area, Malars, Maxilla, and Nasolabial Fold

Midface deflation manifests as loss of malar projection and nasal support, with accentuation of the lower eyelid contour. Photographic, radiographic, and cadaver studies confirm age-related bony loss of the orbit and maxilla, and a posterior rotation of the maxilla leading to a decrease in the maxillary angle and widening of the pyriform aperture.^{49,52-54} These changes are accompanied by

atrophy of inferior lid fat compartments, the sub-orbicularis oculi fat, and laxity of the orbicularis oculi and associated orbitomalar ligament.^{44,46,55,56} The resulting effect on the lower periorbital region is a decrease in the lateral canthal angle, descent of the lateral canthal tendon, loss of lower eyelid tone and hollowing, and the characteristic tear trough deformity (Fig. 9). The deflated midface is marked by prominent transitions between cheek fat pads, flattening of the malar prominence, increased nasolabial fold depth, lengthening of the cutaneous upper lip, and overall loss of lip volume.^{57,58} Consequently, accurate assessment of midface volume loss is the single most important factor for appropriate correction of facial volume, as precise restoration can rejuvenate both the upper and lower face.

We advocate correction of the malars before tear trough, lower lid, and nasolabial fold injection. This holds true for the majority of patients, in whom malar volume loss contributes to nasolabial

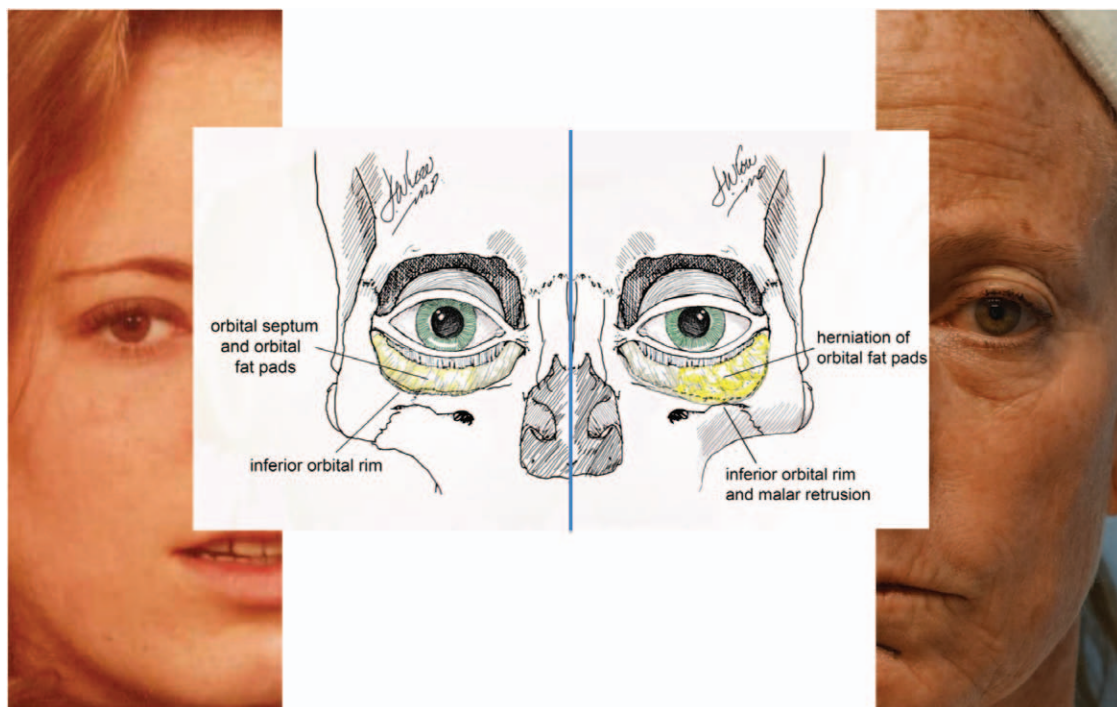


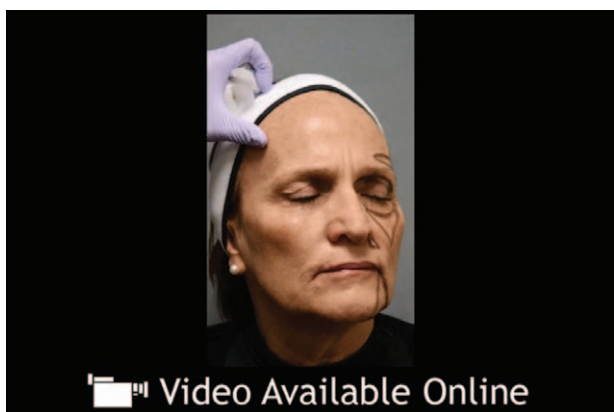
Fig. 9. Lower lid contour is affected by anatomical changes in intrinsic lower lid tissues including atrophy of inferior lid fat compartments, atrophy of the suborbicularis oculi fat, laxity of the orbicularis oculi and associated orbitomalar ligament and, importantly, volume atrophy of the malar region. This constellation of changes is often manifested as a double convexity with prolapsed orbital fat as a superior convexity that is separated from the inferior convexity of the descending malar mound by the skeletonized orbital rim. The medial soft-tissue atrophy of the orbital rim, characterized as the tear trough deformity, or nasojugal groove, extends inferolaterally to accentuate the malar mound and is an easily recognized site of volume atrophy. Less commonly appreciated, however, is the volume atrophy of the lateral orbital rim, which frequently requires augmentation for a cohesive natural result. This image demonstrates the periocular changes that occur with aging. (Left) Patient at age 21 years; (right) patient at age 57 years.

fold severity and the tear trough. The exception, in our opinion, is the rare patient who presents early in the aging process with isolated, fine nasolabial fold rhytides or nasojugal grooves and no discernible malar volume loss. With the exception of Juvederm Voluma XC, no fillers are currently U.S. Food and Drug Administration approved for malar enhancement.^{59,60} Nevertheless, Restylane Lyft, Radiesse, and Juvederm Ultra Plus XC are suitable fillers for deep treatment of the malars, given their elevated G' and n^* (Figs. 1 and 2). Malar injection should be performed in the supra-periosteal or fat pad plane using a depot, stacking, or tower technique, after aspiration. (See **Video, Supplemental Digital Content 3**, which shows a midface volumization with attention to the malar region, available in the “Related Videos” section of the full-text article on www.PRSJournal.com or at <http://links.lww.com/PRS/B694>.) The location of the infraorbital foramen should be appreciated and avoided when treating the anteromedial malar compartment. The quantity of filler used is dependent on the degree of atrophy and product used, typically an average of 1 to 2 cc per side. Careful attention should be paid to restorative effects on the lower lid, nasolabial fold, nasal base, and upper lip during malar augmentation.

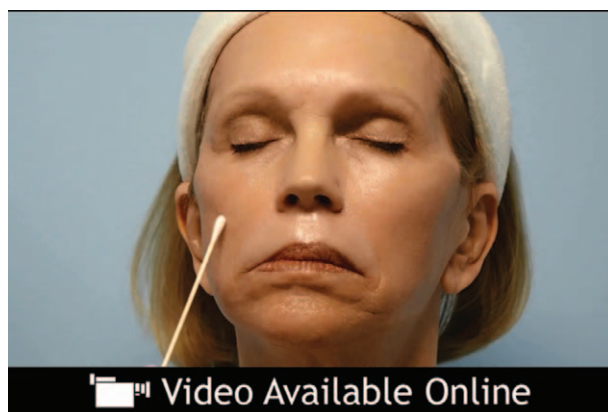
If, following malar augmentation, direct correction of the medial or lateral orbital rim is warranted, we advocate conservative linear threading in the supraperiosteal plane with meticulous preinjection aspiration to avoid intravascular injection and catastrophic retinal artery occlusion.⁶⁰ It should be noted that other injectors have reported equally successful results with alternative techniques. The use of cannulae to

avoid vascular injury and minimize bruising in this area is ideal. (See **Video, Supplemental Digital Content 1**, <http://links.lww.com/PRS/B692>. See **Video, Supplemental Digital Content 4**, which displays a needle-based, sharp technique of nasojugal groove treatment, available in the “Related Videos” section of the full-text article on www.PRSJournal.com or at <http://links.lww.com/PRS/B695>.) Treatment of the crow’s feet as an adjunct to periorbital volumization may be conducted in the deep dermal plane using a threading or crosshatching technique. We prefer Restylane-L, Restylane Silk, or Belotero Balance blended with 1% lidocaine and 1:100,000 epinephrine for volumization of the skeletonized orbital rim and crow’s feet and recommend avoidance of hydrophilic products or those with high G' and n^* profiles in this area. This approach encourages minimal contour deformities, edema, and ecchymoses.

Deep volumization at the level of the nasal sill can provide support to the aging nasal tip; a natural correction of the upper nasolabial fold; and, often, a minor lift to the upper lip. Much like the temple and malar regions, we advocate that enhancement at this level requires periosteal placement of high G' , large-particle fillers. In this approach, the needle is placed at the lateralmost point of the alar base; advanced down to the periosteum, superior to the dentition and deep to the oral mucosa; and, after aspiration, a single depot of filler (approximately 0.3 to 0.5 cc per side) is placed. Injection in this plane should provide a natural restoration of age-related maxillary deficits and avoid the major facial vessels that course in a more superficial plane.



Video 3. Supplemental Digital Content 3, which shows a midface volumization with attention to the malar region, is available in the “Related Videos” section of the full-text article on www.PRSJournal.com or at <http://links.lww.com/PRS/B694>.



Video 4. Supplemental Digital Content 4, which displays a needle-based, sharp technique of nasojugal groove treatment, is available in the “Related Videos” section of the full-text article on www.PRSJournal.com or at <http://links.lww.com/PRS/B695>.

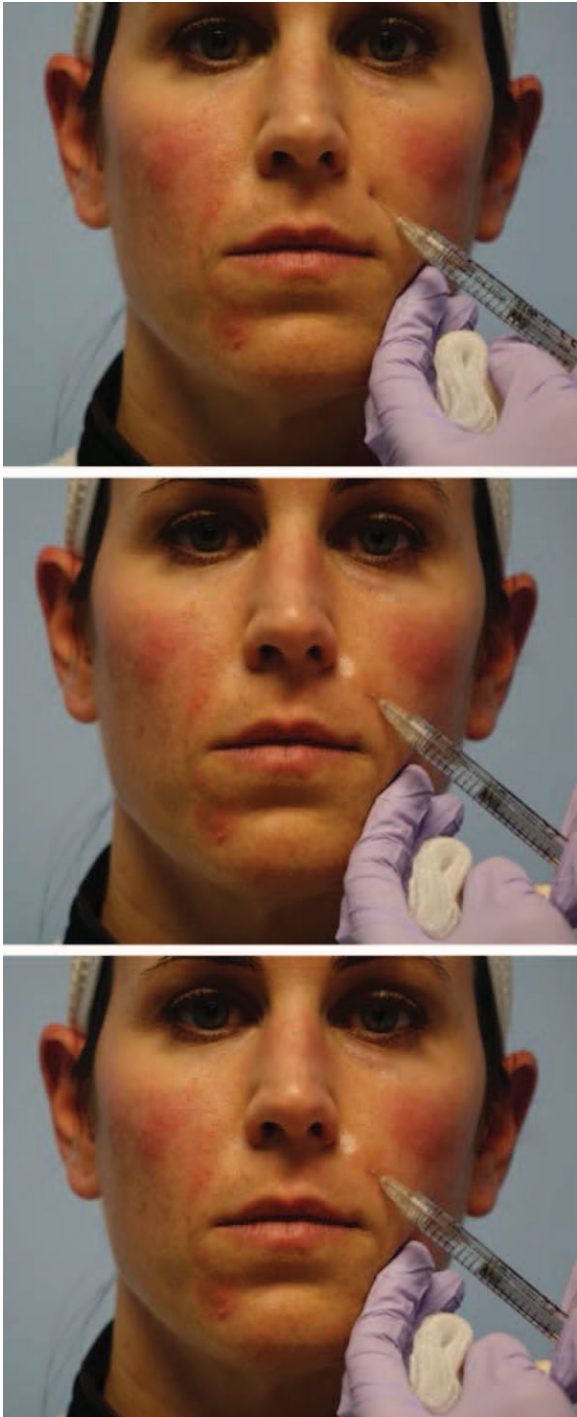


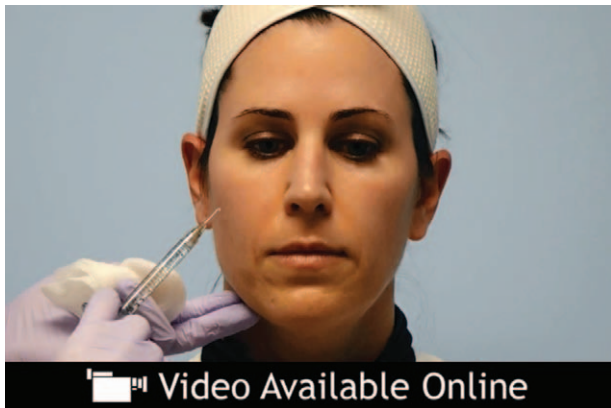Fig. 10. After malar augmentation and correction, direct nasolabial fold correction should be performed with the fanning or retrograde injection technique within and medial to the fold. Augmentation lateral to the fold should be avoided (as this leads to a more prominent defect), as should complete effacement of the fold to prevent the overfilled boxy appearance of the mouth and anterior face. We support treatment of the nasolabial fold with fillers characterized by moderate elasticity and viscosity such as Restylane-L or Juvederm Ultra XC. Injection planes can range from superficial to deep; however, when combined with

Correction of the nasolabial fold merits specific mention. Although this site was the first to be approved by the U.S. Food and Drug Administration for treatment and continues to be the only approved site of injection for many fillers in the United States, we maintain that the nasolabial fold is overtreated and misunderstood. Unlike the remaining face, the nasolabial fold hypertrophies with age. Fillers in this region, in our opinion, should be used to soften a prominent fold and *not* to volumize. Because the nasolabial fold is most often the patient's chief complaint, it is essential for injectors to educate patients that correction of malar volume will more naturally and effectively treat the aging face. We therefore advocate that deficient malar volume should be corrected before the nasolabial fold. Once the malar region has been augmented, the residual nasolabial fold can be softened conservatively (Fig. 10). (See **Video, Supplemental Digital Content 5**, which displays a technique of nasolabial fold filling, available in the "Related Videos" section of the full-text article on www.PRSJournal.com or at <http://links.lww.com/PRS/B696>.)

Lower Face: Jawline, Perioral Area, and Lips

The general widening and loss of integrity of the lower face can be perceived as a relative increase in volume at the jowls with a concomitant decrease in jawline strength and perioral and lip volume. The jowls, characterized anatomically as three fat pads separated by an intervening septum, become more prominent with age secondary to deflation of the superficial fat exposing deeper fat pads, descent of deep fat pads, and increased septal laxity. These changes are exacerbated by volume loss in the region anterior to the jowls, the prejowl sulcus, and volume loss posterior to the masseter in the posterior jawline and inferior preauricular region.^{45,61–64} The perioral area undergoes both superficial and deep atrophy. This is manifested as a lengthening and flattening of the upper lip complex, and a loss of vermilion and vermilion border volume with formation of vertical perioral rhytides (Fig. 11). There is a concomitant downturn of the oral commissure

Fig. 10. (Continued). nasal base augmentation in the supraperiosteal plane, we prefer the superficial subcutaneous plane, just deep to the dermis, to avoid the facial vessels that travel in the deeper subcutaneous tissues and become more superficial as they course superiorly in the face. As with malar and alar base augmentation, injections of the nasolabial fold can be performed with the classic sharp needle or cannula technique.



Video 5. Supplemental Digital Content 5, which displays a technique of nasolabial fold filling, is available in the “Related Videos” section of the full-text article on www.PRSJournal.com or at <http://links.lww.com/PRS/B696>.

and flattening or ptosis of the mentalis region. These changes are superimposed and intensified by mandibular bony changes, resulting in a decrease in vertical ramus height, widening of the mandibular angle, and loss of anterior mandibular (mental) projection.^{62,64}

As with other facial regions, in our opinion, structural volume augmentation of the lower face should begin at the level of the periosteum with correction of the jawline. Fillers with high G' , such as Restylane Lyft, Radiesse, Juvederm Voluma XC, or Juvederm Ultra Plus XC are ideal though used in an off-label fashion (Figs. 1 and 2). Volume augmentation of the posterior and anterior jawline can correct the jowl much like malar augmentation can improve the nasolabial fold. We advocate augmentation of the posterior jawline first to provide support to the anterior jaw and jowls, followed by conservative augmentation of the anterior jaw and prejowl sulcus. Injection along the mandibular border is best performed in the supraperiosteal plane using a depot or threading technique, and the preauricular region is best treated by means of threading in the subcutaneous plane. (See Video, Supplemental Digital Content 6, which displays lower face volumization with a focus on the jawline, marionette lines, and preauricular area, available in the “Related Videos” section of the full-text article on www.PRSJournal.com or at <http://links.lww.com/PRS/B697>.) It is critical to ensure that there is no injury to the parotid gland, marginal mandibular and mental nerves, or facial vessels. Overfilling of the anterior jawline must be avoided to prevent a squared or masculinized appearance of the lower face, which can be further exacerbated by excessive nasolabial fold filling.

We believe the cutaneous lip should be subsequently treated before direct vermilion augmentation (Figs. 12 and 13). (See Video, Supplemental Digital Content 7, which displays perioral volumization of the lips in detail, available in the “Related Videos” section of the full-text article on www.PRSJournal.com or at <http://links.lww.com/PRS/B698>.) Perioral volumization of the upper and lower lip subunits external to the white roll is best conducted with moderate G' fillers such as Restylane-L, Restylane-L Silk, Juvederm Ultra XC, or Belotero Balance in the subcutaneous plane. Restylane-L and Restylane-L Silk both have U.S. Food and Drug Administration approval for augmentation of the lip area. The oral commissure is treated in the subcutaneous plane using a depot technique until a subtle upturning is achieved. The upper and lower lip columns can subsequently be supported in a similar manner by means of volumization the subcutaneous plane external to the white roll. This approach will improve the appearance of vertical lip rhytides and philtral columns and can further be supplemented with direct deep dermal filling of rhytides. In our opinion, perioral volumization independently restores and supports the lips, resulting in enhanced lip volume, and should be conducted before direct mucosal lip augmentation in the aging face. Injection of the perioral area may be conducted by means of standard sharp needle or cannula technique and should avoid, when possible, the robust perioral vasculature.

Complications

Soft-tissue fillers have a low complication rate in the hands of well-trained injectors. It is important, however, to distinguish between side effects and true complications. Generally, tissue trauma resulting in the former is proportional to filler type, volume injected, anatomical location (i.e., lips swell more than malars), and injection technique. Side effects can be minimized by optimization of all preinjection and intrajection variables and meticulous compliance with postprocedure regimens. True complications of injectable fillers, though rare, are best categorized as immediate-, early-, and late-onset events, and can further be subdivided into mild, moderate, and severe as proposed by Sclafani and Fagien in 2009.⁶⁵

Immediate complications are those that occur at the time of injection up to 2 days after injection, and are either related to the amount and properties of the injectable used, or are secondary to vascular compromise.⁶⁶ Regarding the former, irrespective of the anatomical area augmented, the injector must have a profound mastery of the products used

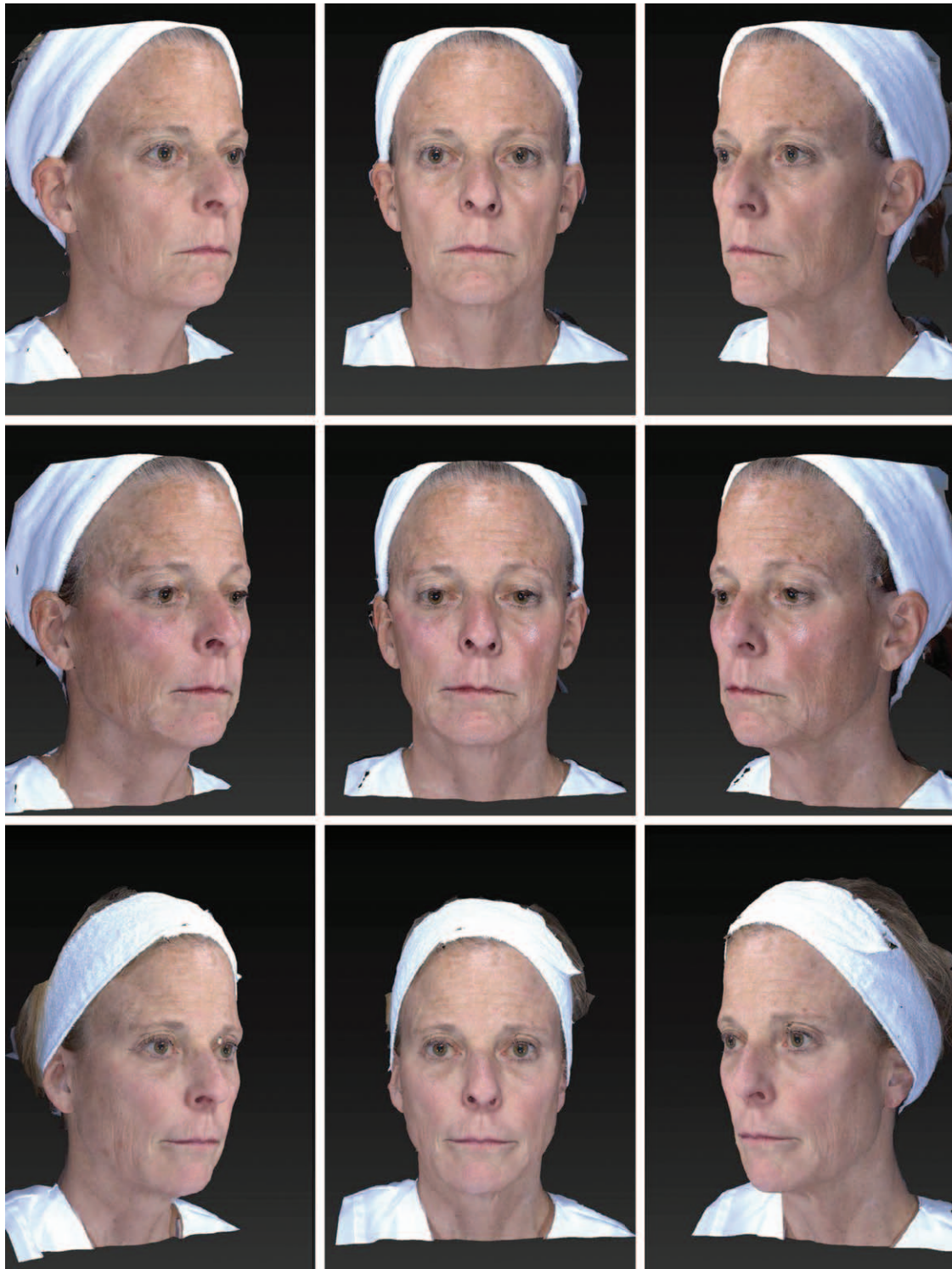
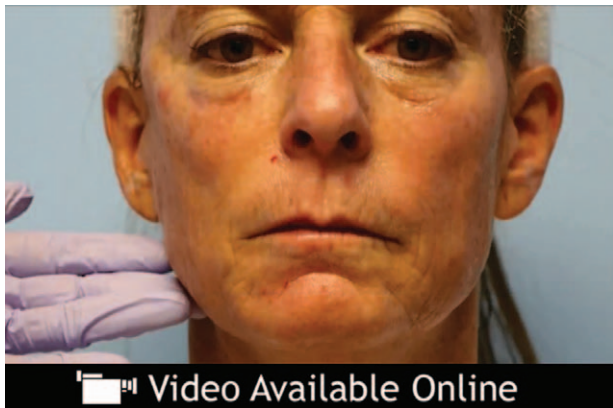
Fig. 11. Three-dimensional assessment of a 57-year-old woman without prior surgical or nonsurgical intervention. The patient underwent volumization of the upper, middle, and lower face. The patient received 2 cc of Juvederm Voluma XC to the bilateral malars, 1 cc to the preauricular region bilaterally, and 1 cc to bilateral jaw lines including prejowl sulcus. In addition, 1.5 cc of Radiesse was placed into each temple. Each lower lid and nasojugal groove was filled with 0.5 cc of Belotero Balance. The perioral region was augmented with 1 cc of Restylane-L in the oral commissure and lip columns and 1 cc of Restylane Silk to the upper and lower lip and vermillion border. (*Center*) The patient following right hemiface augmentation. (*Below*) The patient 2 weeks after augmentation.



Video 6. Supplemental Digital Content 6, which displays lower face volumization with a focus on the jawline, marionette lines, and preauricular area, is available in the “Related Videos” section of the full-text article on www.PRSJournal.com or at <http://links.lww.com/PRS/B697>.

and proper dissolution techniques. To avoid the latter, vascular compromise, the injector is expected to master the three-dimensional anatomy of facial vessels to avoid arterial embolization or occlusion (Fig. 8).⁶⁷⁻⁷⁰ Arterial compromise symptoms include immediate pain, skin blanching in the corresponding anatomical distribution, and skin coolness. Should this occur, the injector must stop immediately, attempt to aspirate the product, and if the product is hyaluronic acid, administer hyaluronidase (i.e., Vitrase; ISTA Pharmaceuticals, Inc., Irvine, Calif.).^{71,72} Some injectors advocate frequent (hourly) hyaluronidase injections after intravascular compromise until signs of tissue compromise improve. Nitropaste can be applied to the compromised area and the patient should be evaluated and treated daily for possible tissue loss. If product is inadvertently injected into a vein, the patient will experience slowly worsening pain and swelling, and

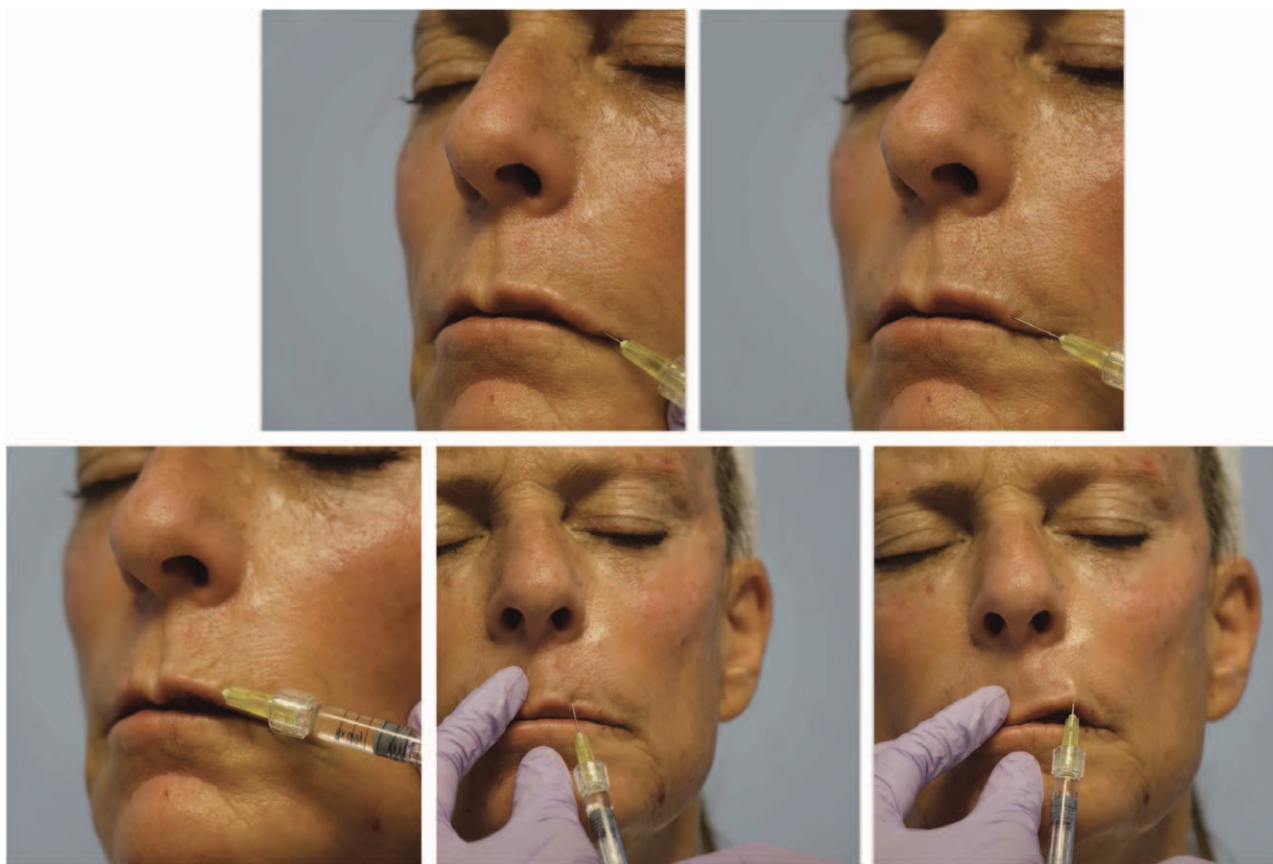

Fig. 12. Vermilion border augmentation. When indicated, direct lip augmentation can be performed. Using a nonhydrophilic filler with a low G' and n^* such as Restylane-L, Restylane-L Silk, or Belotero Balance, the white roll is initially augmented (*above and below, left*). The product should be placed along desired regions of the white roll by means of threading injections in the deep dermal plane that facilitate, when placed correctly, the product traveling along the length of the white roll. Special attention should be paid to augmentation of the cupid's bow, which effaces with age, and avoiding injury to facial vessels that course medially from the lateral quarter of the lips. After enhancement of the vermilion border, vertical perioral rhytides can be filled in the intradermal plane (*below, center, and below, right*).

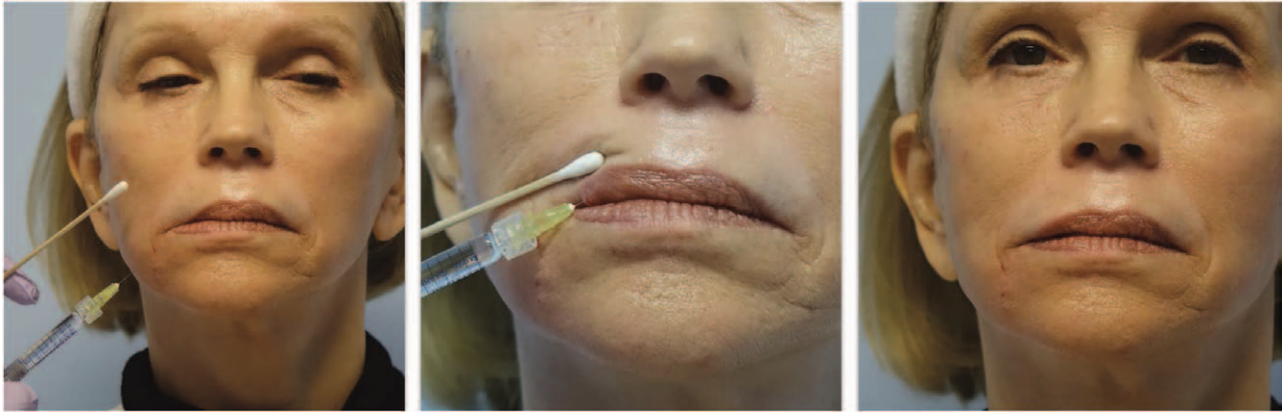

Fig. 13. Direct augmentation of the lip element can be conducted after treatment of the vermilion border but is not always necessary. The threading technique can be used, with the needle entering the wet/dry junction of the vermilion and injection of the product in a retrograde fashion in the submucosal plane superficial to the orbicularis oris muscle. An alternative approach is to inject with the needle approximately 1 cm external to the white roll and directed into the vermilion. We prefer the former approach for the upper lip and the latter for the lower lip. Product deposition depends on areas of volume loss and preexisting lip shape. Volumization of the lip may be conducted by means of standard sharp needle or cannula technique, and overfilling should be avoided. (Left) Baseline volume asymmetry. (Center) With gentle pressure the wet/dry junction of the lip is exposed and product is linearly threaded, in a retrograde fashion. (Right) Improved symmetry following injection.

the affected area will adopt a purplish hue. Typically, venous compromise is caused by overfilling an area, and can be treated by limiting the volume of injectable used and dissolution of the product. Intravascular injection can typically be avoided by intermittent aspiration and judicious cannula use.

Early complications occur within 3 to 14 days after injection and typically are caused by filler-based reactions and inflammation. Up to 2 weeks after injection, it is common for the patient to feel some nodularity in the injected areas. If this persists, however, the nodularity must be defined as either inflammatory or noninflammatory, based on additional symptomatology, including redness, pain, and drainage.^{73–75} Areas with noninflammatory nodules can be gently massaged, or if amenable, the nodules can be dissolved with either a hyaluronidase or intralesional steroid injection. If, however, inflammatory or infectious nodules are evident, a culture specimen may be obtained and sent for Gram stain. The patient may be treated with a course of oral antibiotics (including methicillin-resistant *Staphylococcus aureus* coverage) for roughly 4 to 6 weeks in addition to oral steroids, and followed closely. If possible, the filler should be dissolved to hasten infection resolution. These patients may be considered at higher risk for bio-film formation and should be treated with extreme caution during any subsequent injections.^{9,73,76–78} We advocate a meticulous facial cleansing and preparation regimen, as described earlier under Methodology, to minimize the risk of these complications.



Video 7. Supplemental Digital Content 7, which displays perioral volumization of the lips in detail, is available in the “Related Videos” section of the full-text article on www.PRSJournal.com or at <http://links.lww.com/PRS/B698>.

Late complications occur any time after 14 days, and are associated mainly with the body’s immune reaction to the product. Given that all fillers constitute foreign matter, a patient can form a chronic granuloma that is subject to a low-grade chronic infection manifesting as firm, occasionally painful nodules that may require needle dissolution or, ultimately, surgical excision.

CONCLUSIONS

There have been continuous significant advancements in our understanding of facial aging and structural contouring. Volume loss

from the bony level to the skin results in deflationary changes of the face that can be increasingly addressed successfully with tissue volumizers. Poly-L-lactic acid and autologous fat remain excellent options and are sometimes preferable in specific indications. Hyaluronic acid fillers and, to a lesser extent, calcium hydroxylapatite, however, have become the fillers of choice for the majority of injectors given their relative ease of use, wide array of products, and minimal and rare side effects. We advocate that facial volumization should be approached from deep to superficial tissue planes and in a cephalic-caudal manner. The appropriate filler should be selected based on anatomical site, injector experience, and patient-specific soft-tissue dynamics. Although structural facial volumization using temporary fillers, as described here, has drastically expanded therapeutic options for facial rejuvenation and contouring, this procedure must be used in the appropriate context by properly trained injectors to serve as a valuable component among our multidisciplinary facial restoration techniques.

Ivona Percec, M.D., Ph.D.

Division of Plastic Surgery
University of Pennsylvania
Perelman Center for Advanced Medicine
7th Floor South Pavilion
3400 Civic Center Boulevard
Philadelphia, Pa. 19104

PATIENT CONSENT

Patients provided written consent for the use of their images.

REFERENCES

- Vleggaar D, Fitzgerald R, Lorenc ZP. Understanding, avoiding, and treating potential adverse events following the use of injectable poly-L-lactic acid for facial and nonfacial volumization. *J Drugs Dermatol*. 2014;13(Suppl):s35-s39.
- Lorenc ZP. Techniques for the optimization of facial and nonfacial volumization with injectable poly-L-lactic acid. *Aesthetic Plast Surg*. 2012;36:1222-1229.
- Lorenc ZP, Daro-Kaftan E. Optimizing facial rejuvenation outcomes by combining poly-L-lactic acid, hyaluronic acid, calcium hydroxylapatite, and neurotoxins: Two case studies. *J Drugs Dermatol*. 2014;13:191-195.
- Vleggaar D, Fitzgerald R, Lorenc ZP. The history behind the use of injectable poly-L-lactic acid for facial and nonfacial volumization: The positive impact of evolving methodology. *J Drugs Dermatol*. 2014;13(Suppl):s32-s34.
- Beer K. Dermal fillers and combinations of fillers for facial rejuvenation. *Dermatol Clin*. 2009;27:427-432, v.
- Vleggaar D, Fitzgerald R, Lorenc ZP, et al. Consensus recommendations on the use of injectable poly-L-lactic acid for facial and nonfacial volumization. *J Drugs Dermatol*. 2014;13(Suppl):s44-s51.
- Kontis TC. Contemporary review of injectable facial fillers. *JAMA Facial Plast Surg*. 2013;15:58-64.
- Sundaram H, Voigts B, Beer K, Meland M. Comparison of the rheological properties of viscosity and elasticity in two categories of soft tissue fillers: Calcium hydroxylapatite and hyaluronic acid. *Dermatol Surg*. 2010;36(Suppl 3):1859-1865.
- Bentkover SH. The biology of facial fillers. *Facial Plast Surg*. 2009;25:73-85.
- Hanke CW, Rohrich RJ, Busso M, et al. Facial soft-tissue fillers conference: Assessing the state of the science. *J Am Acad Dermatol*. 2011;64(Suppl):S66-S85, S85.e61-S85.e136.
- Thorne C, Chung KC, Gosain A, Guntner GC, Mehrara BJ. In: Thorne CH, Chung KC, Gosain E, et al., eds. *Grabb and Smith's Plastic Surgery*. 7th ed. Philadelphia: Wolters Kluwer/Lippincott Williams & Wilkins Health; 2014.
- Donofrio LM. Techniques in facial fat grafting. *Aesthet Surg J*. 2008;28:681-687.
- Donofrio LM. Panfacial volume restoration with fat. *Dermatol Surg*. 2005;31:1496-1505.
- Winters R, Moulthrop T. Is autologous fat grafting superior to other fillers for facial rejuvenation? *Laryngoscope*. 2013;123:1068-1069.
- Donofrio LM. Fat rebalancing: The new "facelift". *Skin Therapy Lett*. 2002;7:7-9.
- Donofrio LM. Fat distribution: A morphologic study of the aging face. *Dermatol Surg*. 2000;26:1107-1112.
- Coleman SR. Facial augmentation with structural fat grafting. *Clin Plast Surg*. 2006;33:567-577.
- Lindqvist C, Tveten S, Bondevik BE, Fagrell D. A randomized, evaluator-blind, multicenter comparison of the efficacy and tolerability of Perlane versus Zyplast in the correction of nasolabial folds. *Plast Reconstr Surg*. 2005;115:282-289.
- Carruthers A, Carey W, De Lorenzi C, Remington K, Schachter D, Sapra S. Randomized, double-blind comparison of the efficacy of two hyaluronic acid derivatives, Restylane Perlane and Hylaform, in the treatment of nasolabial folds. *Dermatol Surg*. 2005;31:1591-1598; discussion 1598.
- Rohrich RJ, Ghavami A, Crosby MA. The role of hyaluronic acid fillers (Restylane) in facial cosmetic surgery: Review and technical considerations. *Plast Reconstr Surg*. 2007;120(Suppl):41S-54S.
- Lorenc ZP, Fagien S, Flynn TC, Waldorf HA. Review of key Belotero Balance safety and efficacy trials. *Plast Reconstr Surg*. 2013;132(Suppl 2):33S-40S.
- Narins RS, Brandt F, Leyden J, Lorenc ZP, Rubin M, Smith S. A randomized, double-blind, multicenter comparison of the efficacy and tolerability of Restylane versus Zyplast for the correction of nasolabial folds. *Dermatol Surg*. 2003;29:588-595.
- Morris CL, Stinnett SS, Woodward JA. Patient-preferred sites of Restylane injection in periocular and facial soft-tissue augmentation. *Ophthalm Plast Reconstr Surg*. 2008;24:117-121.
- Emilson A, Johansson C, Wong C. Multidose of Restylane for facial augmentation. *Arch Facial Plast Surg*. 2010;12:433; author reply 433-434.
- Matarasso SL, Carruthers JD, Jewell ML; Restylane Consensus Group. Consensus recommendations for soft-tissue augmentation with nonanimal stabilized hyaluronic acid (Restylane). *Plast Reconstr Surg*. 2006;117(Suppl):3S-34S; discussion 35S.
- Dover JS, Carruthers A, Carruthers J, Alam M. Clinical use of Restylane. *Skin Therapy Lett*. 2005;10:5-7.
- Kablik J, Monheit GD, Yu L, Chang G, Gershkovich J. Comparative physical properties of hyaluronic acid dermal fillers. *Dermatol Surg*. 2009;35(Suppl 1):302-312.

28. Beasley KL, Weiss MA, Weiss RA. Hyaluronic acid fillers: A comprehensive review. *Facial Plast Surg.* 2009;25:86–94.
29. Edsman K, Nord LI, Ohrlund A, Lärkner H, Kenne AH. Gel properties of hyaluronic acid dermal fillers. *Dermatol Surg.* 2012;38:1170–1179.
30. Buck DW II, Alam M, Kim JY. Injectable fillers for facial rejuvenation: A review. *J Plast Reconstr Aesthet Surg.* 2009;62:11–18.
31. Niamtu J III. Filler injection with micro-cannula instead of needles. *Dermatol Surg.* 2009;35:2005–2008.
32. Mole B. Accordion wrinkle treatment through the targeted use of botulinum toxin injections. *Aesthet Plast Surg.* 2014;38:419–428.
33. Hsu VM, Wes AM, Tahiri Y, Cornman-Homonoff J, Percec I. Quantified facial soft-tissue strain in animation measured by real-time dynamic 3-dimensional imaging. *Plast Reconstr Surg Glob Open* 2014;2:e211.
34. Bartlett SP, Grossman R, Whitaker LA. Age-related changes of the craniofacial skeleton: An anthropometric and histologic analysis. *Plast Reconstr Surg.* 1992;90:592–600.
35. Coleman SR, Grover R. The anatomy of the aging face: Volume loss and changes in 3-dimensional topography. *Aesthet Surg J.* 2006;26(Suppl):S4–S9.
36. Farkas JP, Pessa JE, Hubbard B, Rohrich RJ. The science and theory behind facial aging. *Plast Reconstr Surg Glob Open* 2013;1:e8–e15.
37. Kahn DM, Shaw RB Jr. Aging of the bony orbit: A three-dimensional computed tomographic study. *Aesthet Surg J.* 2008;28:258–264.
38. Kahn DM, Shaw RB. Overview of current thoughts on facial volume and aging. *Facial Plast Surg.* 2010;26:350–355.
39. Lambros V. Observations on periorbital and midface aging. *Plast Reconstr Surg.* 2007;120:1367–1376; discussion 1377.
40. Lambros V. Models of facial aging and implications for treatment. *Clin Plast Surg.* 2008;35:319–327; discussion 327.
41. Mendelson B, Wong CH. Changes in the facial skeleton with aging: Implications and clinical applications in facial rejuvenation. *Aesthetic Plast Surg.* 2012;36:753–760.
42. Mendelson BC, Hartley W, Scott M, McNab A, Granzow JW. Age-related changes of the orbit and midcheek and the implications for facial rejuvenation. *Aesthetic Plast Surg.* 2007;31:419–423.
43. Pessa JE, Rohrich RJ. Discussion: Aging changes of the midfacial fat compartments: A computed tomographic study. *Plast Reconstr Surg.* 2012;129:274–275.
44. Rohrich RJ, Pessa JE. The fat compartments of the face: Anatomy and clinical implications for cosmetic surgery. *Plast Reconstr Surg.* 2007;119:2219–2227; discussion 2228–2231.
45. Rohrich RJ, Pessa JE. The anatomy and clinical implications of perioral submuscular fat. *Plast Reconstr Surg.* 2009;124:266–271.
46. Rohrich RJ, Pessa JE, Ristow B. The youthful cheek and the deep medial fat compartment. *Plast Reconstr Surg.* 2008;121:2107–2112.
47. Lambros V. Volumizing the brow with hyaluronic acid fillers. *Aesthet Surg J.* 2009;29:174–179.
48. Rohrich RJ, Arbiqwe GM, Wong C, Brown S, Pessa JE. The anatomy of suborbicularis fat: Implications for periorbital rejuvenation. *Plast Reconstr Surg.* 2009;124:946–951.
49. Shaw RB Jr, Katzel EB, Koltz PF, et al. Aging of the facial skeleton: Aesthetic implications and rejuvenation strategies. *Plast Reconstr Surg.* 2011;127:374–383.
50. Ross JJ, Malhotra R. Orbitofacial rejuvenation of temple hollowing with Perlane injectable filler. *Aesthet Surg J.* 2010;30:428–433.
51. Moradi A, Shirazi A, Moradi J. A 12-month, prospective, evaluator-blinded study of small gel particle hyaluronic acid filler in the correction of temporal fossa volume loss. *J Drugs Dermatol.* 2013;12:470–475.
52. Shaw RB Jr, Kahn DM. Aging of the midface bony elements: A three-dimensional computed tomographic study. *Plast Reconstr Surg.* 2007;119:675–681; discussion 682.
53. Pessa JE, Zadoo VP, Mutimer KL, et al. Relative maxillary retrusion as a natural consequence of aging: Combining skeletal and soft-tissue changes into an integrated model of midfacial aging. *Plast Reconstr Surg.* 1998;102:205–212.
54. Pessa JE, Zadoo VP, Yuan C, et al. Concertina effect and facial aging: Nonlinear aspects of youthfulness and skeletal remodeling, and why, perhaps, infants have jowls. *Plast Reconstr Surg.* 1999;103:635–644.
55. Mendelson BC. Anatomic study of the retaining ligaments of the face and applications for facial rejuvenation. *Aesthetic Plast Surg.* 2013;37:513–515.
56. Gierloff M, Stöhring C, Buder T, Gassling V, Açil Y, Wiltfang J. Aging changes of the midfacial fat compartments: A computed tomographic study. *Plast Reconstr Surg.* 2012;129:263–273.
57. Tan SL, Brandt MG, Yeung JC, Doyle PC, Moore CC. The aesthetic unit principle of facial aging. *JAMA Facial Plast Surg.* 2015;17:33–38.
58. Pilsil U, Anderhuber F, Rzany B. Anatomy of the cheek: Implications for soft tissue augmentation. *Dermatol Surg.* 2012;38:1254–1262.
59. Philipp-Dormston WG, Eccleston D, De Boule K, Hilton S, van den Elzen H, Nathan M. A prospective, observational study of the volumizing effect of open-label aesthetic use of Juvéderm Voluma with lidocaine in mid-face area. *J Cosmet Laser Ther.* 2014;16:171–179.
60. De Pasquale A, Russa G, Pulvirenti M, Di Rosa L. Hyaluronic acid filler injections for tear-trough deformity: Injection technique and high-frequency ultrasound follow-up evaluation. *Aesthetic Plast Surg.* 2013;37:587–591.
61. Reece EM, Pessa JE, Rohrich RJ. The mandibular septum: Anatomical observations of the jowls in aging—implications for facial rejuvenation. *Plast Reconstr Surg.* 2008;121:1414–1420.
62. Pessa JE, Slice DE, Hanz KR, Broadbent TH Jr, Rohrich RJ. Aging and the shape of the mandible. *Plast Reconstr Surg.* 2008;121:196–200.
63. Reece EM, Rohrich RJ. The aesthetic jaw line: Management of the aging jowl. *Aesthet Surg J.* 2008;28:668–674.
64. Shaw RB Jr, Katzel EB, Koltz PF, Kahn DM, Giroto JA, Langstein HN. Aging of the mandible and its aesthetic implications. *Plast Reconstr Surg.* 2010;125:332–342.
65. Sclafani AP, Fagien S. Treatment of injectable soft tissue filler complications. *Dermatol Surg.* 2009;35(Suppl 2):1672–1680.
66. Beleznav K, Humphrey S, Carruthers JD, Carruthers A. Vascular compromise from soft tissue augmentation: Experience with 12 cases and recommendations for optimal outcomes. *J Clin Aesthet Dermatol.* 2014;7:37–43.
67. Carruthers JD, Fagien S, Rohrich RJ, Weinkle S, Carruthers A. Blindness caused by cosmetic filler injection: A review of cause and therapy. *Plast Reconstr Surg.* 2014;134:1197–1201.
68. Lee JG, Yang HM, Choi YJ, et al. Facial arterial depth and relationship with the facial musculature layer. *Plast Reconstr Surg.* 2015;135:437–444.
69. Yang HM, Lee JG, Hu KS, et al. New anatomical insights on the course and branching patterns of the facial artery: Clinical implications of injectable treatments to the nasolabial fold and nasojugal groove. *Plast Reconstr Surg.* 2014;133:1077–1082.

70. Phumyoo T, Tansatit T, Rachkeaw N. The soft tissue landmarks to avoid injury to the facial artery during filler and neurotoxin injection at the nasolabial region. *J Craniofac Surg*. 2014;25:1885–1889.
71. Lambros V. The use of hyaluronidase to reverse the effects of hyaluronic acid filler. *Plast Reconstr Surg*. 2004;114:277.
72. Rao V, Chi S, Woodward J. Reversing facial fillers: Interactions between hyaluronidase and commercially available hyaluronic-acid based fillers. *J Drugs Dermatol*. 2014;13:1053–1056.
73. Ledon JA, Savas JA, Yang S, Franca K, Camacho I, Nouri K. Inflammatory nodules following soft tissue filler use: A review of causative agents, pathology and treatment options. *Am J Clin Dermatol*. 2013;14:401–411.
74. Poveda R, Bagán JV, Murillo J, Jiménez Y. Granulomatous facial reaction to injected cosmetic fillers: A presentation of five cases. *Med Oral Patol Oral Cir Bucal*. 2006;11:E1–E5.
75. Hachach-Haram N, Gregori M, Kirkpatrick N, Young R, Collier J. Complications of facial fillers: Resource implications for NHS hospitals. *BMJ Case Rep*. 2013;2013:pii: bcr-2012-007141.
76. Schütz P, Ibrahim HH, Hussain SS, Ali TS, El-Bassuoni K, Thomas J. Infected facial tissue fillers: Case series and review of the literature. *J Oral Maxillofac Surg*. 2012;70:2403–2412.
77. Ferneini EM. Infected facial tissue fillers. *J Oral Maxillofac Surg*. 2013;71:240.
78. Rohrich RJ, Monheit G, Nguyen AT, Brown SA, Fagien S. Soft-tissue filler complications: The important role of bio-films. *Plast Reconstr Surg*. 2010;125:1250–1256.